



Medical Imagery

## Corrosive Injury of Upper Gastrointestinal Tract Caused by Hand Warmer

Chien-Ming Chiu<sup>a</sup>, Sung-Yuan Hu<sup>b,c,d,e\*</sup>

<sup>a</sup> Department of Emergency Medicine, Taichung Veterans General Hospital, Taichung, Taiwan, <sup>b</sup> School of Medicine, <sup>c</sup> Institute of Medicine, Chung Shan Medical University, Taichung, Taiwan, <sup>d</sup> Department of Nursing, College of Health, National Taichung University of Science and Technology, Taichung, Taiwan, <sup>e</sup> Department of Nursing, Central Taiwan University of Science and Technology, Taichung, Taiwan

ARTICLE INFO

Accepted 25 March 2019

### Medical imagery

An 84-year-old Taiwanese man with a history of dementia was referred to our emergency department (ED) owing to unintentional ingestion of one packet of hand warmer with a size of 13 × 9.5 cm and a weight of 60 g at 15:00PM after gastric lavage at a local clinic. Kidney-ureter-bladder (Fig. 1A) revealed retention of radiopaque particles in the stomach and small intestine. Laboratory investigations were unremarkable except 227 µg/dl of serum iron (reference range: 60–160 µg/dl) at 20:00PM. Esophagogastroduodenoscopy (EGD) showed ulcers near esophagogastric junction and multiple erosions in stomach and duodenum with iron deposits (Fig. 1B). Twenty four hours later, serum iron was 84 µg/dl. He was discharged with oral sucralfate and outpatient follow-up with free symptoms of the gastrointestinal tract.

The hand warmer may lead to corrosive injury of the esophagus and stomach through a simple exothermic reaction to gas and fluid in the gastrointestinal tract by exposing its contents (50% iron powder, 20% activated charcoal, 3% vermiculite, and 2% salt). Activated charcoal, vermiculite, and salts are non-toxic substances, but iron poisoning caused by absorption of ferric chloride through mixing iron oxides with hydrochloric acid in stomach can be considered with transiently increased serum iron concentration. Exothermic reaction which may reach a temperature of 87 °C is a potential risk of thermal injury to the gastrointestinal tract. Although unintentional ingestion of one packet may not cause significant mortality or morbidity, early and effective gastrointestinal decontamination with gastric lavage and EGD are recommended as soon as possible in patients intoxicated by hand warmer.<sup>1,2</sup> A close observation in an ED is suggested for 6 hours at least until the clinical toxic symptoms or signs are elucidated.<sup>2</sup> Although unintentional ingestion of hand warmers is rare, emergency physicians must keep the potential toxicity associated with iron in mind, especially in the elderly.

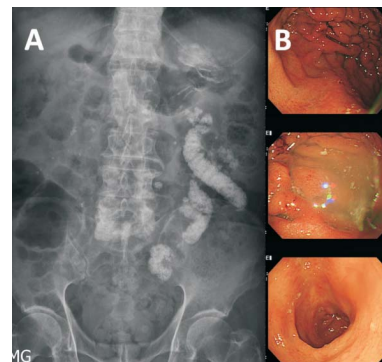
### Funding

This research received no specific grant from any funding agency in the public, commercial, or not-for-profit sectors.

### Competing interests

The authors declared that there were no competing interests

\* Corresponding author. 1650 Taiwan Boulevard Sect. 4, Taichung 40705, Taiwan.  
E-mail address: [song9168@pie.com.tw](mailto:song9168@pie.com.tw) (S.-Y. Hu)



**Fig. 1.** Kidney-ureter-bladder revealed retention of radiopaque particles in the stomach and small intestine (A). Esophagogastroduodenoscopy showed ulcers near esophagogastric junction (upper picture in B) and erosions in stomach (middle picture in B) and duodenum (lower picture in B) with iron deposits.

regarding the publication of this paper.

### Availability of data and material

All data and material presented in the article were available upon request.

### Ethics approval and consent to participate

Ethical approval was not required, but the patient's informed consent and agreement of images for publication were completed.

### Authors' contributions

CM Chiu and SY Hu contributed to clinical survey at emergency department. CM Chiu and SY Hu drafted the manuscript. All authors contributed to paper preparation.

### References

1. Tseng YJ, Chen CH, Chen WK, et al. Hand warmer related corrosive injury. *Clin Toxicol (Phila)*. 2011;49:870–871.
2. Weiland JL, Sherrow LK, Jayant DA, et al. Chemical hand warmer packet ingestion: A case of elemental iron exposure. *Wilderness Environ Med*. 2017;28:246–248.